



# The groin triangle: a patho-anatomical approach to the diagnosis of chronic groin pain in athletes

E C Falvey,<sup>1,2</sup> A Franklyn-Miller,<sup>2</sup> P R McCrory<sup>1</sup>

<sup>1</sup> Centre for Health, Exercise and Sports Medicine, School of Physiotherapy, Faculty of Medicine, Dentistry and Health Sciences, The University of Melbourne, Victoria, Australia; <sup>2</sup> Olympic Park Sports Medicine Centre, Melbourne, Australia

Correspondence to:  
Dr E C Falvey, Sports Surgery Clinic, Santry Demesne, Dublin 9, Ireland; e.falvey@mac.com

Accepted 6 March 2008  
Published Online First  
16 November 2008

## ABSTRACT

Chronic groin pain is a common presentation in sports medicine. It is most often a problem in those sports that involve kicking and twisting movements while running. The morbidity of groin pain should not be underestimated, ranking behind only fracture and anterior cruciate ligament reconstruction in terms of time out of training and play. Due to the insidious onset and course of pathology in the groin region it commonly presents with well-established pathology. Without a clear clinical/pathological diagnosis, the subsequent management of chronic groin pain is difficult. The combination of complex anatomy, variability of presentation and the non-specific nature of the signs and symptoms make the diagnostic process problematical. This paper proposes a novel educational model based on patho-anatomical concepts. Anatomical reference points were selected to form a triangle, which provides the discriminative power to restrict the differential diagnosis and form the basis of ensuing investigation. This paper forms part of a series addressing the three-dimensional nature of proximal lower limb pathology. The 3G approach (groin, gluteal and greater trochanter triangles) acknowledges this, permitting the clinician to move throughout the region, considering pathologies appropriately.

Chronic groin pain is a common presentation in sports medicine practice. Studies in professional sports have found groin injury to be the fourth most common injury affecting soccer players,<sup>1</sup> the third most common injury in Australian rules football<sup>2</sup> and it also has a high prevalence in ice hockey<sup>3</sup> and rugby.<sup>4,5</sup>

This gives an incomplete portrayal, however, as the morbidity attached to chronic groin pain means it is behind only fracture and joint reconstruction in terms of lost time from injury.<sup>4,5</sup>

All these sports involve kicking and twisting movements while running. These actions place a strain on fascial and musculoskeletal structures that are fixed to a number of bony anatomical points in close proximity. The resultant tissue damage and/or entrapment of anatomical structures may cause pain.

This paper sets out a method based on patho-anatomical principles for a systematic examination of the chronically painful groin, which enables the clinician to discriminate more easily between pathological conditions and target their investigation and subsequent management to specific diagnoses.

## THE GROIN TRIANGLE

The specific anatomical landmarks and borders of the groin triangle are set out in fig 1.

## APEX POINTS OF THE GROIN TRIANGLE

The anatomical apex points of the triangle are as follows: the anterior superior iliac spine (ASIS); the pubic tubercle and the 3G (groin, gluteal and greater trochanter triangles) point.

## The 3G point

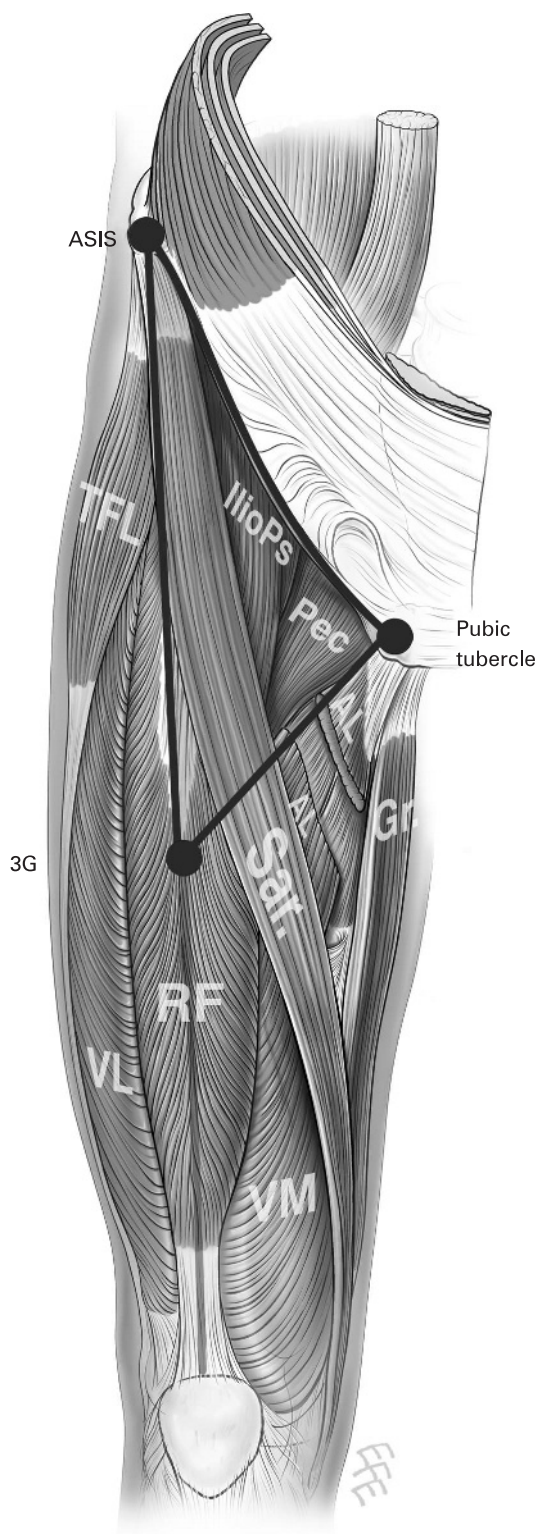
From anthropometric measurements, the authors defined a new reference point at the apex of the triangle. This point was termed the "3G point" in reference to the three-dimensional pathology and the groin, gluteal and greater trochanteric regions. The relationship of this point in the anterior coronal plane was the mid-distance point between the ASIS and the superior pole of the patella, and in the posterior coronal plane double the distance from the spinous process of the L5 lumbar vertebrae to the ischial tuberosity in the line of the femur.

## ANATOMICAL RELATIONS OF THE BORDERS OF THE GROIN TRIANGLE

### Superior border of the groin triangle

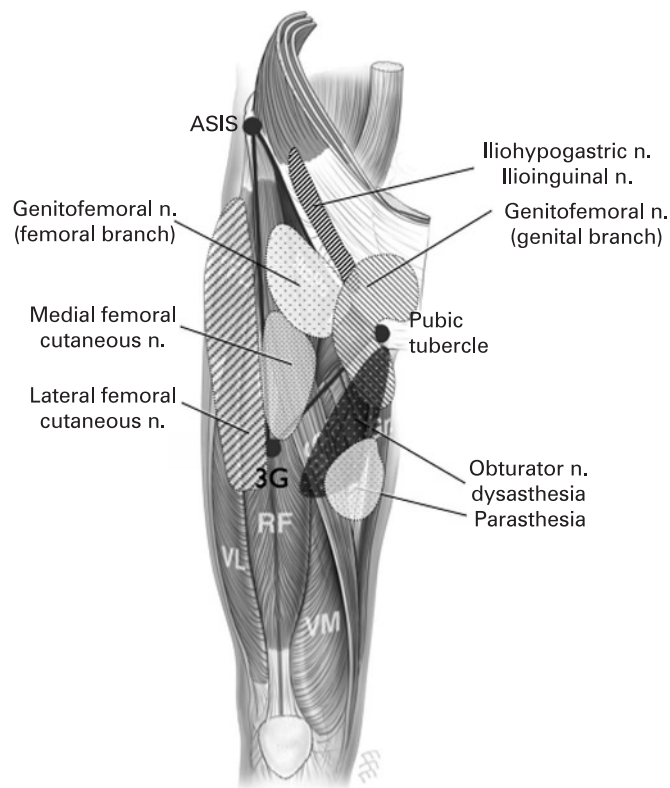
The line between the pubic tubercle and the ASIS forms the superior border of the triangle. This corresponds to the anatomical position of the inguinal ligament, a thickening of the aponeurosis of the external oblique muscle. Superior to this line, working from the pubic tubercle medially to the ASIS laterally the following structures will be encountered: the rectus abdominis and rectus abdominis sheath insertions; internal oblique, external oblique and transversus abdominis insertions and aponeuroses; inguinal canal, medially the superficial inguinal ring and conjoint tendon, more laterally the canal and further laterally the deep inguinal ring; the ilioinguinal, iliohypogastric and genital branch of the genitofemoral nerve; the conjoint tendon of ilio-psoas as it passes under the lateral third of the inguinal ligament; the visceral contents of the abdomen and pelvis.

The insertion of the rectus abdominis and its sheath are intimately related to the aponeuroses of the obliques and transversus abdominis. The junction of where these structures converge at the pubic bone revolves around the inguinal canal. The internal inguinal ring is located at a point between the mid-inguinal point (situated midway between the anterior superior iliac spine and the pubic symphysis) and the midpoint of the inguinal ligament.<sup>6</sup> The transversalis fascia and the conjoint tendon, a confluence of internal oblique and transversalis fasciae, form the posterior wall of the canal. The superficial inguinal ring, the opening in the external oblique aponeurosis is situated a



**Figure 1** The groin triangle. AL, adductor longus; ASIS, anterior superior iliac spine; Gr, gracilis; IlioPS, iliopsoas; Pec, pectineus; RF, rectus femoris; Sar, sartorius; TFL, tensor fasciae latae; 3G, the 3G point; VL, vastus lateralis; VM, vastus medialis.

centimetre above and lateral to the pubic tubercle. The anatomy of the ilioinguinal and iliohypogastric and genital branch of the genitofemoral nerves is extremely variable, between them they supply the skin of the lower abdomen, medial thigh and scrotum.<sup>7</sup>



**Figure 2** Neuropathy of the proximal lower limb. ASIS, anterior superior iliac spine; Gr, gracilis; RF, rectus femoris; 3G, the 3G point; VL, vastus lateralis; VM, vastus medialis.

### Medial border of the groin triangle

The line from the pubic tubercle to the 3G point inferiorly forms the medial border of the triangle. Although neither the medial or lateral borders of the triangle comprise a muscular line, in both instances they work to separate the clinically important “groups” of structures that lie on either side of them. Medial to the border lie the adductor muscles, from superficial to deep—adductor longus, gracilis, adductor brevis, adductor magnus.

The adductor longus and gracilis tendons are the most commonly affected and lie in an almost continuous site of origin along the body of the pubis. The other adductor muscles (brevis and magnus) arise more posterolaterally along the inferior pubic ramus. The ramus forms a direct continuum between the pubic body and the ischial tuberosity. The obturator nerve divides in the obturator canal (2–3 cm long canal situated in the anterosuperior aspect of the obturator foramen containing the obturator nerve, artery and vein) to anterior and posterior divisions. The anterior branch innervates the adductor longus, brevis, gracilis and, occasionally, the pectineus; it supplies sensory innervation to the skin and fascia of the inner distal thirds of the medial thigh.<sup>8</sup>

### Lateral border of triangle

The line from the ASIS superiorly to the 3G point forms the lateral border of the triangle: femoro-acetabular joint; trochanteric bursa; tensor fasciae latae and iliotibial band.

Although the surface marking of the femoro-acetabular joint lies within the triangle, the pathology of the joint is usually referred to as the greater trochanter, as such it is considered in this section. Gluteal bursae underlie the gluteus maximus and

**Table 1** Patho-anatomical approach: pubic tubercle region (diagnoses appear in order of frequency in an athletic population)

Define and align	Pathology	Listen and localise	Palpate and re-create	Alleviate and investigate
Pubic tubercle	Adductor tendon enthesopathy	Insidious onset, warms up with exercise	Guarding on passive abduction, <sup>9</sup> weakness. <sup>10</sup> Pubic "clock": 6–8	Magnetic resonance imaging <sup>11</sup>
	Rectus abdominis enthesopathy	Well localised to insertion, acute or insidious onset	Pain from resisted sit-up. <sup>10</sup> Pubic "clock": 12	Magnetic resonance imaging <sup>11</sup>
	Pubic bone stress injury	Non-specific diminished athletic performance, loss of propulsive power	Bone tenderness predominates <sup>12–13</sup> Diagnosis of exclusion	Plain film, <sup>13</sup> magnetic resonance imaging <sup>14</sup>
	Degenerative pubic symphysis	Central pain, associated with stress through symphysis—stair climbing	Tender over symphysis. Pubic "clock": 3	Plain film, stress view, <sup>15</sup> magnetic resonance imaging <sup>14</sup>
	Incipient hernia; conjoint tendon tear	Insidious onset, diminished performance, warms up	Pain on resisted "torsion" of trunk "ipsilateral direction". <sup>16</sup> Pubic "clock": 11	Ultrasound <sup>17</sup>
	Incipient hernia; external oblique aponeurosis tear	Acute onset, related to sport-specific movement eg, "slap shot". <sup>22</sup>	Pain on resisted "torsion" of trunk "contralateral direction". <sup>16</sup> Tenderness and dilation of superficial inguinal ring on invagination of scrotum. <sup>23</sup> Pubic "clock": 12–1	Magnetic resonance imaging <sup>18</sup> Confirmation by direct vision at arthroscopy <sup>19–21</sup>
	Nerve entrapment; ilioinguinal nerve	Altered skin sensation	Superficial pain with or without hyper/dysaesthesia to skin over pubis. <sup>26</sup>	Relief of pain by ultrasound-guided local anaesthetic infiltration <sup>27</sup>
Genitofemoral nerve (genital branch)	Post inguinal surgery? <sup>24</sup>	Absence of muscular component <sup>28</sup>	Nerve conduction studies <sup>7</sup>	

gluteus medius tendons proximal to their insertions. The iliotibial band or tract is a lateral thickening of the fasciae latae in the thigh. Proximally it splits into superficial and deep layers, enclosing tensor fasciae latae and anchoring this muscle to the iliac crest.

### Within the triangle

Within the triangle the following structures are encountered: conjoint tendon of the iliopsoas muscle; rectus femoris muscle; femoral canal.

The psoas arises as a series of slips, each of which arise from the adjacent margins of the vertebral bodies and the intervening discs from the lower border of T12 to the upper border of L5. The iliacus arises from the upper two-thirds of the concavity of the iliac fossa and the inner lip of the iliac crest, as well as the ventral sacro-iliac and iliolumbar ligaments and the upper surface of the lateral part of the sacrum. The two muscles converge and pass downwards and medially beneath the inguinal ligament over the hip joint and into the lesser trochanter of the femur. The passage of this conjoined tendon

over the hip joint is facilitated by the iliopsoas bursa, which is in some cases in direct communication with the hip joint. The rectus femoris arises via a direct head from the anterior inferior iliac spine and a reflected head arising from the superior acetabular rim and joint capsule. The femoral ring is the base of the femoral canal. Its surface marking is medial to the femoral artery, palpable at the mid-inguinal point. The femoral ring is bounded in front by the inguinal ligament, behind by the pectineus, medially by the crescentic base of the lacunar ligament and laterally by the fibrous septum on the medial side of the femoral vein.

### Nerve entrapment

The classic distribution of the cutaneous innervation of the area incorporated in the triangle and their potential neuropathies is shown in fig 2; these, however, must serve as a guide only, as in vivo considerable variation occurs.<sup>7, 26, 28–30</sup> The clinician will appreciate that in addition to paraesthesias, a compressed nerve can give rise to pain. The additional possibility of referred or radicular pain from T12, L1, L2 and L3 must also be considered.

**Table 2** Patho-anatomical approach: medial to the groin triangle (diagnoses appear in order of frequency in an athletic population)

Define and align	Pathology	Listen and localise	Palpate and re-create	Alleviate and investigate
Medial to triangle	Adductor/gracilis enthesopathy	Insidious onset, diminished performance, warms up	Proximal adductor pain, at enthesis. Guarding, weakness <sup>9, 10</sup>	Magnetic resonance imaging <sup>11</sup>
	Adductor longus pathology at musculotendinous junction	Acute onset, worse during exercise	Pain in proximal adductor <sup>10</sup> (2–4 cm distal to enthesis), guarding, weakness <sup>9, 10</sup>	Magnetic resonance imaging <sup>11</sup>
	Pubic bone stress injury	Pain primarily at pubis radiating to proximal thigh	Bone tenderness, lack of point muscular tenderness	Magnetic resonance imaging <sup>11, 31</sup>
	Stress fracture inferior pubic ramus	Insidious onset, heavy training load	Hop test, <sup>32</sup> associated deep buttock pain	Plain x ray, magnetic resonance imaging <sup>33</sup>
	Nerve entrapment	Claudicant-type pain of medial thigh, which settles on resting <sup>34</sup>	Exercise-related adductor weakness, superficial dysesthesia of mid-medial thigh <sup>35</sup>	Electromyography of adductor longus <sup>36</sup> Guided local anaesthetic injection to obturator foramen <sup>37</sup>
	I. Obturator nerve			
	II. Ilioinguinal nerve	Altered skin sensation	Dysaesthesia/hyperaesthesia over area of skin supplied by nerve in question <sup>24, 25</sup>	Relief of pain by ultrasound-guided local anaesthetic infiltration <sup>27</sup> Nerve conduction studies <sup>7</sup>
	III. Genitofemoral nerve (genital branch)	Post inguinal surgery?		
External iliac artery endofibrosis	Thigh discomfort post high-intensity exercise mainly in cyclists	Exercise-related lower limb weakness, exercise-altered bruit and ankle/brachial index <sup>38</sup>	Doppler ultrasound <sup>39</sup> Angiography <sup>40</sup>	



**Table 3** Patho-anatomical approach: superior to the groin triangle (diagnoses appear in order of frequency in an athletic population)

Define and align	Pathology	Listen and localise	Palpate and re-create	Alleviate and investigate
Superior to base	Rectus abdominis tendinopathy	Well localised to insertion, acute or insidious onset	Pain from resisted sit-up. <sup>10 41</sup> Pubic "clock": 12	Magnetic resonance imaging <sup>11</sup>
	Incipient hernia; conjoint tendon tear	Insidious onset, diminished performance, warms up	Pain on resisted "torsion" of trunk "ipsilateral direction". <sup>16</sup> Pubic "clock": 11	Ultrasound <sup>17</sup>
	Incipient hernia; external oblique aponeurosis tear	Acute onset, related to sport-specific movement, eg, "slap shot" <sup>122</sup>	Pain on resisted "torsion" of trunk "contralateral direction" <sup>16</sup>	Magnetic resonance imaging <sup>18</sup>
	Inguinal hernia	Pain on valsalva manoeuvre	Tenderness and dilation of superficial inguinal ring on invagination of scrotum <sup>23</sup> Pubic "clock": 12–1	Confirmation by direct vision at arthroscopy <sup>19–21</sup>
	Nerve entrapment Ilioinguinal nerve	Altered skin sensation	Cough impulse, palpable mass at deep inguinal ring (direct), in inguinal canal/scrotum (indirect)	Ultrasound <sup>17</sup> Herniography, <sup>42</sup> laparoscopy
	Iliohypogastric nerve Genitofemoral nerve (genital branch) Lateral femoral cutaneous nerve		Dysaesthesia/hyperaesthesia over area of skin supplied by nerve in question <sup>7 25</sup>	Relief of pain by ultrasound-guided local anaesthetic infiltration <sup>27</sup> Nerve conduction studies <sup>7</sup>

### A PATHO-ANATOMICAL APPROACH USING THE GROIN TRIANGLE

The diagnostic process of history and examination is often abbreviated. There is a growing tendency to rely on investigational studies as the initial diagnostic step (eg, proceeding to magnetic resonance imaging of a painful groin in the absence of a clear differential diagnosis). The authors propose a four-step approach to the diagnostic process emphasising history and examination and limiting investigation to the final step as follows.

#### Step 1: define and align

Define the anatomical points and borders of the triangle on the patient (ASIS, pubic tubercle and 3G point).

#### Step 2: listen and localise

Listen to the patient's history and obtain as many localising factors as possible, then pinpoint the pain in relation to the groin triangle.

#### Step 3: palpate and re-create

Carefully palpate the identified area and determine which anatomical structures are painful. The use of provocative manoeuvres/examinations (eg, exercise) to re-create the patient's pain can be a critical diagnostic step. To describe all

of the manoeuvres in detail is beyond the scope of this text; readers are referred to reviews on this topic.<sup>32 43</sup>

#### Step 4: alleviate and investigate

When a number of anatomical structures are in close proximity, clinical presentations can be very similar. The manner in which pain can be removed may be very helpful. A decrease in pain following abstinence from aggravating activity is revealing. If a distinct structure can be identified, the elimination of symptoms following guided injection of local anaesthetic into the structure is invaluable. The authors recognise that a number of conditions discussed in this text may only be diagnosed definitively following radiological investigation; in these instances the most discriminative, evidence-based investigation is recommended.

### SPECIFIC SCENARIOS USING A PROBLEM-ORIENTED APPROACH

The diagnostic stepwise approach using the groin triangle is summarised in tables 1–5. The triangle is used to localise the pathology to a particular area. We refer the reader to the specific table relating to that border of the triangle. This provides a differential diagnosis and clarifies the most discriminative evidence-based tests.

**Table 4** Patho-anatomical approach: lateral to the groin triangle (diagnoses appear in order of frequency in an athletic population)

Define and align	Pathology	Listen and localise	Palpate and re-create	Alleviate and investigate
Lateral to triangle	Impingement/labral pathology, femoro-acetabular joint	Mechanical signs, clicking in joint and/or catching	Impingement test <sup>44</sup>	Magnetic resonance imaging, arthrogram <sup>45</sup>
	Osteoarthritis/chondral damage, femoro-acetabular joint	History of traumatic/congenital insult. Older age group	Limited range of movement, <sup>46</sup> pain on weight bearing	Plain film x ray, magnetic resonance imaging <sup>33</sup>
		Persistent lateral hip pain worse on lying on affected side	Pain on transition between lying/standing <sup>47</sup>	Ultrasound. <sup>48</sup> Relief of pain by ultrasound-guided local anaesthetic injection
	Iliotibial band friction syndrome	External "snapping" and/or lateral knee pain	Re-create snapping <sup>49</sup> Ober's test <sup>32</sup>	Ultrasound <sup>48</sup>
	Stress fracture neck of femur	Heavy training load, biomechanical/gait abnormality	Hop test, <sup>50</sup> fulcrum test <sup>51</sup>	Plain film x ray, Magnetic resonance imaging <sup>33</sup>
	Nerve entrapment; lateral cutaneous femoral nerve/meralgia paraesthetica	Exercise induced, obesity <sup>52</sup>	Reproduction of symptoms on pressure inferior to anterior superior iliac spine <sup>52</sup>	Nerve conduction studies <sup>7</sup>

**Table 5** Patho-anatomical approach: within the groin triangle (diagnoses appear in order of frequency in an athletic population)

Define and align	Pathology	Listen and localise	Palpate and re-create	Alleviate and investigate
Within the triangle	Iliopsoas syndrome	Pain above and below inguinal ligament—associated snapping at hip joint	Thomas test, modified <sup>32</sup>	Ultrasound scan dynamic view of snapping <sup>48</sup> with or without injection <sup>53</sup>
	Rectus femoris tendinopathy/apophysitis	Does knee movement affect pain?	Rectus femoris contracture test <sup>54</sup>	Magnetic resonance imaging Plain x ray, ultrasound scan <sup>48</sup>
	Femoral hernia	Painful lump inferomedial to pubic tubercle	Minimal relationship to exercise	Magnetic resonance imaging Ultrasound scan <sup>17</sup>
	Nerve entrapment Genitofemoral nerve (femoral branch) Medial femoral cutaneous nerve	Altered skin sensation	Dysaesthesia/hypaesthesia over area of skin supplied by nerve in question <sup>5</sup>	Herniography <sup>42</sup> Relief of pain by local anaesthetic infiltration <sup>27</sup> Nerve conduction studies <sup>7</sup>

### PUBIC TUBERCLE

Because many potentially anatomical structures converge at this point, we propose a marking of the structure in similar fashion to a clock face (fig 3, table 1). This schematic representation of the anatomy of the area serves as a guide to what may be palpable following invagination of the scrotum. The examining clinician can therefore “walk their finger” around the tubercle assigning each part of the clock face to the relevant attachment as highlighted in fig 3. The authors recognise the variability of structures in this area, having based diagrams on cadaveric studies performed prior to this paper.<sup>55</sup> We have employed the term “pubic bone stress injury” for what is often in the literature called “osteitis pubis”. We feel this is a better reflection of the clinical picture in the absence of any evidence of an inflammatory process.

The topic of incipient hernia is included as disorders of the posterior and anterior inguinal walls. These are diagnoses of exclusion and, outside of the most experienced hands, probably inseparable. These may represent different ends of a spectrum of pathology in the area as a result of differing sporting activity.<sup>3 19 22 23 56</sup>

### MEDIAL TO THE TRIANGLE

Adductor longus pathology is the most common cause of pain in this area; differentiation of enthesis-related problems from those at the musculotendinous junction is important. The abnormal mechanics that arise as a result of adductor dysfunction play a critical role in the generation of a chronic pain/dysfunction cycle in the area (fig 4, table 2).

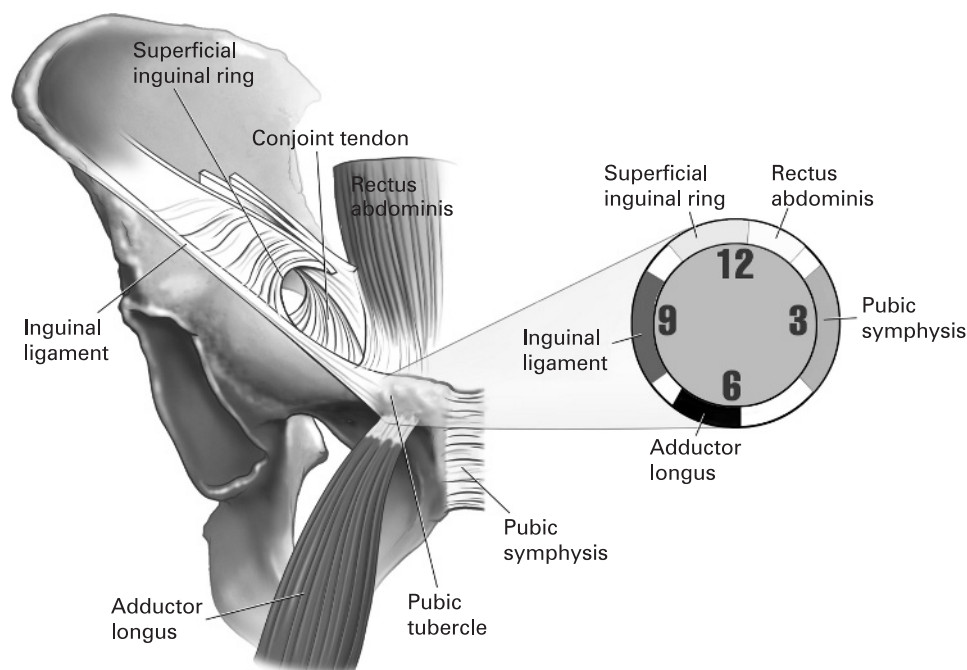
### SUPERIOR TO THE TRIANGLE

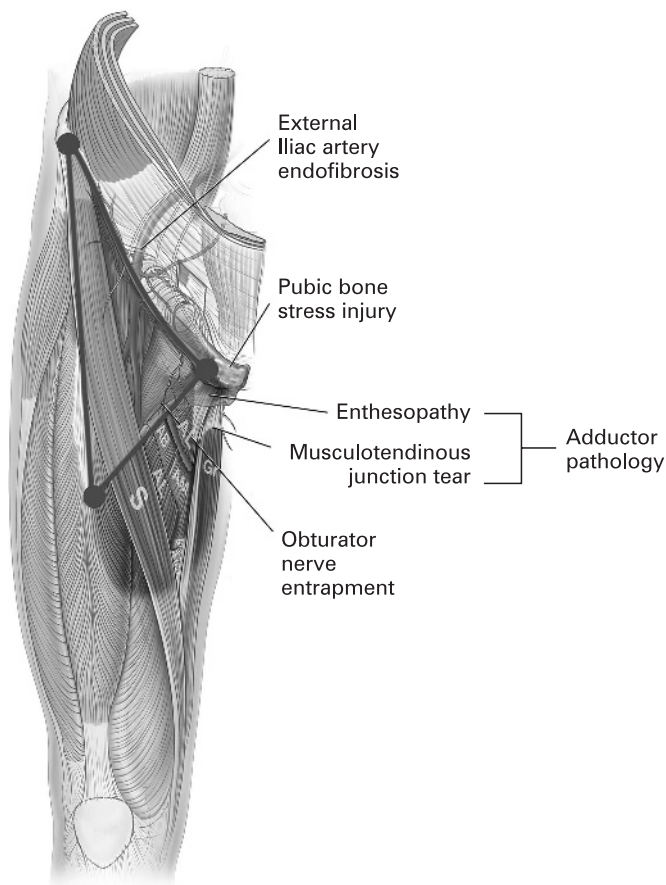
Rectus abdominis pathology tends to be well localised to its insertion at the pubic tubercle, often making it the most clearcut diagnosis in this area. This may arise as a primary diagnosis, or develop secondary to pubic overload originating from adductor or iliopsoas pathology (fig 5, table 3).

### LATERAL TO THE TRIANGLE

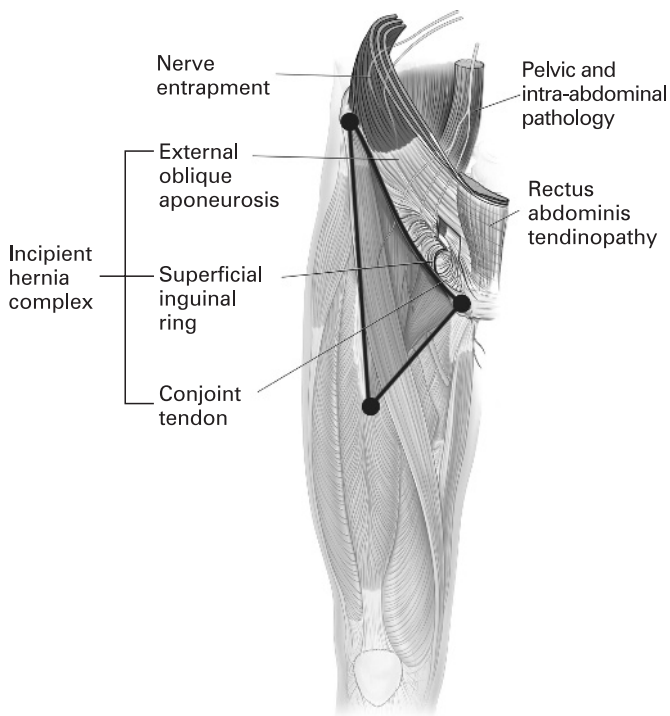
As a cause of recalcitrant groin pain, pathology of the femoro-acetabular joint should not be underestimated. The joint is prone to degenerative, inflammatory and infective processes. The long-term contribution of acute or repetitive trauma to the

**Figure 3** The pubic clock.

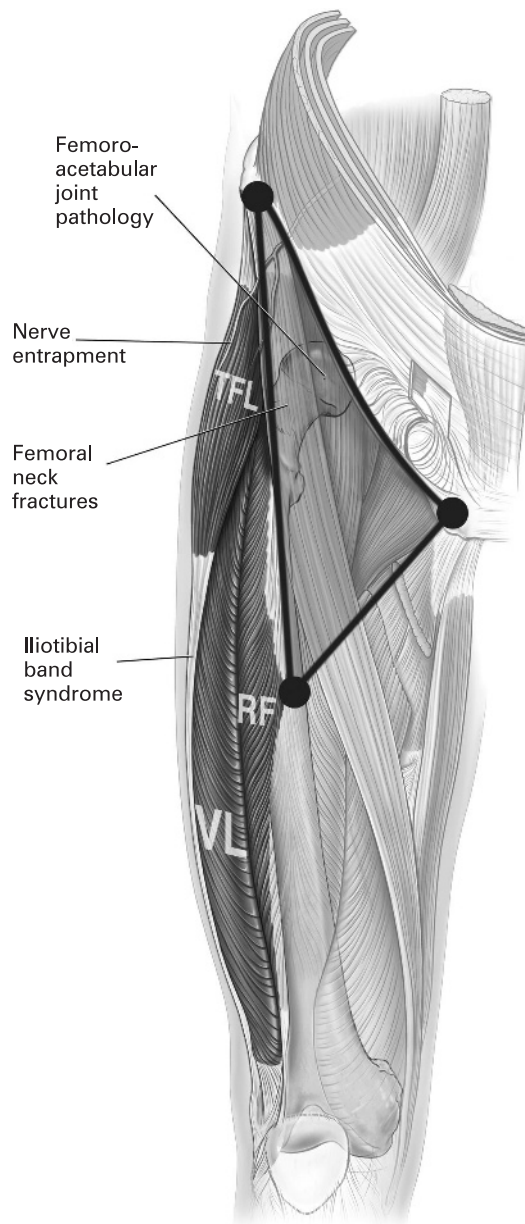




**Figure 4** Medial to the triangle. AB, adductor brevis; AL, adductor longus; AM, adductor magnus; Gr, gracilis; S, sartorius.



**Figure 5** Superior to the triangle.



**Figure 6** Lateral to the triangle. RF, rectus femoris; TFL, tensor fasciae latae; VL, vastus lateralis.

development of degenerative conditions such as osteoarthritis is of particular concern in the sports setting (fig 6, table 4).

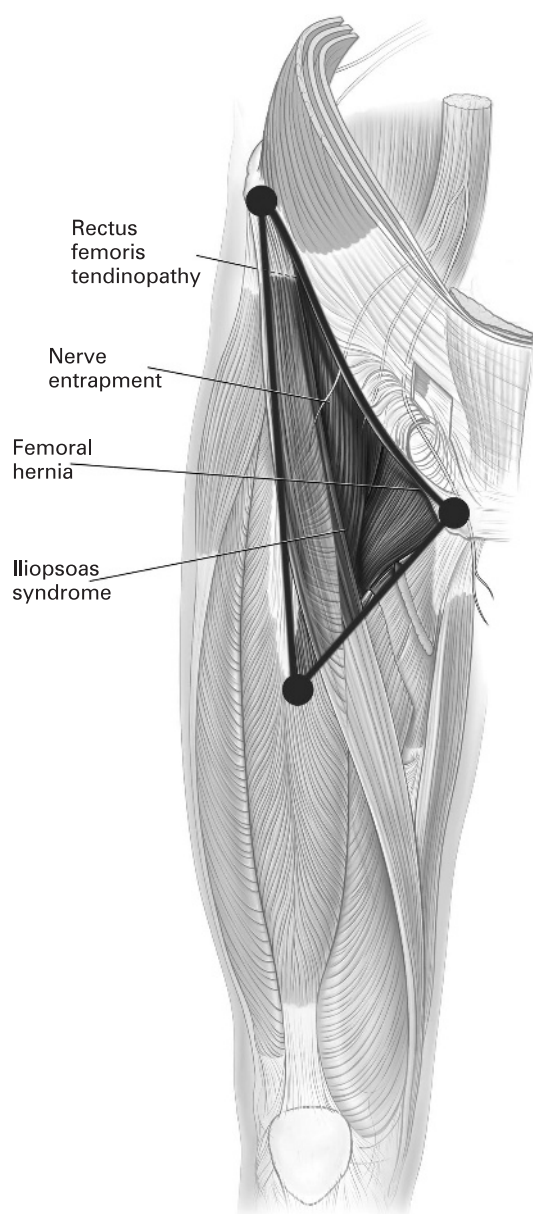
**WITHIN THE TRIANGLE**

Pathology of the iliopsoas muscle may cause pain that is referred in the area superior to the triangle, but the conjoint tendon is the most palpable structure within the triangle when the hip is flexed. This is a common, although underdiagnosed, cause of groin pain.<sup>57</sup> It is particularly prone to irritation when overloaded secondary to dysfunction of other muscular structures around the groin, such as the adductors (fig 7, table 5).

**INTRA-ABDOMINAL PATHOLOGY**

Discussion of this topic is beyond the scope of this paper; gastrointestinal and genitourinary pathology may mask as groin discomfort or pain. Key discriminating symptoms may be signs of systemic illness, systemic inflammatory response and no





**Figure 7** Within the triangle.

correlation between exercise and symptoms or signs. Any or all of the above in conjunction with a negative musculoskeletal examination serve to alert the examining physician to focus their examinations beyond the musculoskeletal system.

## CONCLUSION

This paper presents a method of teaching the causes of chronic groin pain. By offering a systematic means of limiting the differential diagnosis through history examination, diagnostic manoeuvres and, when necessary, directed investigation, this method may help the less experienced clinician with the diagnostic process.

The groin triangle is one section of the “3G” approach to teaching the causes of chronic pain in the proximal lower limb. This paper should therefore be read in conjunction with the gluteal and greater trochanter triangle papers to address the three-dimensional nature of the region fully.

## What this paper adds

- ▶ This paper outlines a novel educational approach to the categorisation of pathologies in the groin area in an athlete.
- ▶ Pain-generating structures are categorised according to their anatomical position, around a triangle based on easily located anatomical landmarks.
- ▶ This categorisation, with accompanying high-quality diagrams, focuses the diagnostic process. Discriminative questioning and evidence-based examination presented in tabular form facilitate accurate differential diagnosis.

Experience and a thorough knowledge of the anatomy of the region remain vital in any complete understanding of groin pain. By providing a means of focusing the differential diagnosis in a structured manner, practitioners who lack expertise may approach this problem with more confidence.

**Competing interests:** None.

## REFERENCES

1. **Walden M**, Hagglund M, Ekstrand J. Football injuries during European Championships 2004–2005. *Knee Surg Sports Traumatol Arthrosc* 2007;
2. **Orchard J**, Seward H. Epidemiology of injuries in the Australian Football League, seasons 1997–2000. *Br J Sports Med* 2002;**36**:39–44.
3. **Emery CA**, Meeuwisse WH, Powell JW. Groin and abdominal strain injuries in the National Hockey League. *Clin J Sport Med* 1999;**9**:151–6.
4. **Brooks JH**, Fuller CW, Kemp SP, *et al*. Epidemiology of injuries in English professional rugby union: Part 2. Training injuries. *Br J Sports Med* 2005;**39**:767–75.
5. **Brooks JH**, Fuller CW, Kemp SP, *et al*. Epidemiology of injuries in English professional rugby union: Part 1. Match injuries. *Br J Sports Med* 2005;**39**:757–66.
6. **Koliyadan SV**, Narayan G, Balasekran P. Surface marking of the deep inguinal ring. *Clin Anat (NY)* 2004;**17**:554–7.
7. **Rab M**, Ebmer And J, Dellon AL. Anatomic variability of the ilioinguinal and genitofemoral nerve: implications for the treatment of groin pain. *Plastic Reconstruct Surg* 2001;**108**:1618–23.
8. **McCroary P**, Bell S, Bradshaw C. Nerve entrapments of the lower leg, ankle and foot in sport. *Sports Med (Auckland)* 2002;**32**:371–91.
9. **Kendall FP**, McCreary E. ME, eds. Lower extremity muscles. In: *Muscles – testing and function*. Williams and Wilkins, 1983:158–79.
10. **Holmich P**, Holmich LR, Bjerg AM. Clinical examination of athletes with groin pain: an intraobserver and interobserver reliability study. *Br J Sports Med* 2004;**38**:446–51.
11. **Zoga AC**, Kavanagh EC, Omar IM, *et al*. Athletic pubalgia and the “sports hernia”: MR imaging findings. *Radiology* 2008;**247**:797–807.
12. **Lynch SA**, Renstrom PA. Groin injuries in sport: treatment strategies. *Sports Med (Auckland)* 1999;**28**:137–44.
13. **Fricke PA**, Taunton JE, Ammann W. Osteitis pubis in athletes. Infection, inflammation or injury? *Sports Med (Auckland)* 1991;**12**:266–79.
14. **Lovell G**, Galloway H, Hopkins W, *et al*. Osteitis pubis and assessment of bone marrow edema at the pubic symphysis with MRI in an elite junior male soccer squad. *Clin J Sport Med* 2006;**16**:117–22.
15. **LaBan MM**, Meerschaert JR, Taylor RS, *et al*. Symphyseal and sacroiliac joint pain associated with pubic symphysis instability. *Arch Phys Med Rehabil* 1978;**59**:470–2.
16. **Kumar S**. Ergonomics and biology of spinal rotation. *Ergonomics* 2004;**47**:370–415.
17. **van den Berg JC**, Rutten MJ, de Valois JC, *et al*. Masses and pain in the groin: a review of imaging findings. *Eur Radiol* 1998;**8**:911–21.
18. **Nelson EN**, Kassirjian A, Palmer WE. MR imaging of sports-related groin pain. *Magnet Reson Imag Clin North Am* 2005;**13**:727–42.
19. **Kluin J**, den Hoed PT, van Linschoten R, *et al*. Endoscopic evaluation and treatment of groin pain in the athlete. *Am J Sports Med* 2004;**32**:944–9.
20. **Kumar A**, Doran J, Batt ME, *et al*. Results of inguinal canal repair in athletes with sports hernia. *J R Coll Surg (Edinburgh)* 2002;**47**:561–5.
21. **Steele P**, Annear P, Grove JR. Surgery for posterior inguinal wall deficiency in athletes. *J Sci Med Sport/Sports Med Aust* 2004;**7**:415–21; discussion 22–3.
22. **Irshad K**, Feldman LS, Lavoie C, *et al*. Operative management of “hockey groin syndrome”: 12 years of experience in National Hockey League players. *Surgery* 2001;**130**:759–64; discussion 64–6.
23. **Gilmore J**. Groin pain in the soccer athlete: fact, fiction, and treatment. *Clin Sports Med* 1998;**17**:787–93, vii.
24. **Lizka TG**, Dellon AL, Manson PN. Iliohypogastric nerve entrapment following abdominoplasty. *Plast Reconstruct Surg* 1994;**93**:181–4.
25. **Harms BA**, DeHaas DR Jr, Starling JR. Diagnosis and management of genitofemoral neuralgia. *Arch Surg* 1984;**119**:339–41.

26. **Lee CH**, Dellon AL. Surgical management of groin pain of neural origin. *J Am Coll Surgeons* 2000;**191**:137–42.
27. **Eichenberger U**, Greher M, Kirchmair L, et al. Ultrasound-guided blocks of the ilioinguinal and iliohypogastric nerve: accuracy of a selective new technique confirmed by anatomical dissection. *Br J Anaesth* 2006;**97**:238–43.
28. **Krahenbuhl L**, Striffeler H, Baer HU, et al. Retroperitoneal endoscopic neurectomy for nerve entrapment after hernia repair. *Br J Surg* 1997;**84**:216–19.
29. **Morikawa R**. [Distribution and variations of the nerves deriving from the lumbar plexus and supplying the abdominal wall]. *Kaibogaku Zasshi* 1971;**46**:312–38.
30. **Starling JR**, Harms BA. Diagnosis and treatment of genitofemoral and ilioinguinal neuralgia. *World J Surg* 1989;**13**:586–91.
31. **Verrall GM**, Slavotinek JP, Barnes PG, et al. Assessment of physical examination and magnetic resonance imaging findings of hamstring injury as predictors for recurrent injury. *J Orthopaed Sports Phys Ther* 2006;**36**:215–24.
32. **Malanga GA**, Nadler SF. Physical examination of the hip. In: *Musculoskeletal physical examination, an evidence-based approach*. Philadelphia, PA: Elsevier Mosby, 2006:251–79.
33. **Berger FH**, de Jonge MC, Maas M. Stress fractures in the lower extremity. The importance of increasing awareness amongst radiologists. *Eur J Radiol* 2007;**62**:16–26.
34. **Bradshaw C**, McCrory P, Bell S, et al. Obturator nerve entrapment. A cause of groin pain in athletes. *Am J Sports Med* 1997;**25**:402–8.
35. **Bradshaw C**, McCrory P. Obturator nerve entrapment. *Clin J Sport Med* 1997;**7**:217–19.
36. **Delagi E**, Perotto A. *Anatomic guide for the electromyographer*, 2nd ed. Springfield: Charles C Thomas Publishers, 1980.
37. **Magora F**, Rozin R, Ben-Menachem Y, et al. Obturator nerve block: an evaluation of technique. *Br J Anaesth* 1969;**41**:695–8.
38. **Abraham P**, Bickert S, Vielle B, et al. Pressure measurements at rest and after heavy exercise to detect moderate arterial lesions in athletes. *J Vasc Surg* 2001;**33**:721–7.
39. **Abraham P**, Leftheriotis G, Bourre Y, et al. Echography of external iliac artery endofibrosis in cyclists. *Am J Sports Med* 1993;**21**:861–3.
40. **Abraham P**, Chevalier JM, Saumet JL. External iliac artery endofibrosis: a 40-year course. *J Sports Med Phys Fitness* 1997;**37**:297–300.
41. **Meyers WC**, Foley DP, Garrett WE, et al. Management of severe lower abdominal or inguinal pain in high-performance athletes. PAIN (Performing Athletes with Abdominal or Inguinal Neuromuscular Pain Study Group). *Am J Sports Med* 2000;**28**:2–8.
42. **Garner JP**, Patel S, Glaves J, et al. Is herniography useful? *Hernia* 2006;**10**:66–9.
43. **Brukner PD**, Khan KM. *Clinical sports medicine*, 3rd ed. Sydney: McGraw Hill, 2006.
44. **Ganz R**, Parvizi J, Beck M, et al. Femoroacetabular impingement: a cause for osteoarthritis of the hip. *Clin Orthopaed Relat Res* 2003;**417**:112–20.
45. **Leunig M**, Podeszwa D, Beck M, et al. Magnetic resonance arthrography of labral disorders in hips with dysplasia and impingement. *Clin Orthopaed Relat Res* 2004;**418**:74–80.
46. **Birrell F**, Croft P, Cooper C, et al. Predicting radiographic hip osteoarthritis from range of movement. *Rheumatology (Oxford)* 2001;**40**:506–12.
47. **Bird PA**, Oakley SP, Shnier R, et al. Prospective evaluation of magnetic resonance imaging and physical examination findings in patients with greater trochanteric pain syndrome. *Arthritis Rheum* 2001;**44**:2138–45.
48. **Allen GM**, Wilson DJ. Ultrasound in sports medicine—a critical evaluation. *Eur J Radiol* 2007;**62**:79–85.
49. **Brignall CG**, Brown RM, Stainsby GD. Fibrosis of the gluteus maximus as a cause of snapping hip. A case report. *J Bone Joint Surg Am* 1993;**75**:909–10.
50. **Monteleone GP Jr**. Stress fractures in the athlete. *Orthoped Clin North Am* 1995;**26**:423–32.
51. **Johnson AW**, Weiss CB Jr, Wheeler DL. Stress fractures of the femoral shaft in athletes—more common than expected. A new clinical test. *Am J Sports Med* 1994;**22**:248–56.
52. **Seror P**, Seror R. Meralgia paresthetica: clinical and electrophysiological diagnosis in 120 cases. *Muscle Nerve* 2006;**33**:650–4.
53. **Adler RS**, Buly R, Ambrose R, et al. Diagnostic and therapeutic use of sonography-guided iliopsoas peritendinous injections. *AJR Am J Roentgenol* 2005;**185**:940–3.
54. **Magee D**. *Orthopedic physical examination*, 4th ed. Philadelphia: WB Saunders, 2002.
55. **Franklin-Miller A**, Falvey EC, McCrory P, et al. Landmarks for the 3G approach: groin, gluteal, and greater trochanter triangles, a pathoanatomical method in sports medicine. *Eur J Anat* 2008; in press.
56. **Lovell G**. The diagnosis of chronic groin pain in athletes: a review of 189 cases. *Aust J Sci Med Sport* 1995;**27**:76–9.
57. **Holmich P**. Long-standing groin pain in sportspeople falls into three primary patterns – a “clinical entity” approach: prospective study of 207 patients. *Br J Sports Med* 2007;**41**:247–52.

### Quality & Safety in Health Care

*Quality & Safety in Health Care* is a leading international peer-review journal in the growing area of quality and safety improvement. It provides essential information for those wanting to reduce harm and improve patient safety and the quality of care. The journal reports and reflects research, improvement initiatives and viewpoints and other discursive papers relevant to these crucial aims with contributions from researchers, clinical professionals and managers and experts in organisational development and behaviour.

qshc.bmj.com

Quality  
& Safety  
in Health Care